

Early Detection of the Hoof Diseases in Holstein Cows Using Thermovision Camera

Tina BOBIĆ
Pero MIJIĆ
Maja GREGIĆ (✉)
Ante BAGARIĆ
Vesna GANTNER

Summary

Aiming early detection of the tissue changes (sole ulcer - SU, interdigital hyperplasia - IH, dermatitis - D) of the hooves in dairy cows. The measurement of the surface temperature of hooves were conducted by a thermovision camera. The study was conducted in Holstein cows which they did not have any visually noticeable changes in the movement (lameness). Measurement of temperature of coronary band (CB) of the front and rear legs was made. For statistical analysis (ANOVA) program Statistica (2012) was used. After the examination of all the isolated cows suspected of having some tissue changes, it was determined that 63% of cows that had some kind of tissue change on a minimum one hoof, while the 37% of cows were without any changes that is estimates of elevated temperature of the tissue with the thermovision camera gave a negative result. It was determined the 14% of the hooves with SU, 24% IH and the 62% with D tissue changes. Statistically highly significant ($p < 0.05$; $p < 0.0001$) difference in maximum, minimum and mean measured temperature of CB on the hooves of cows were determined between the non-lesion and lesion hoofs. Statistically significant ($p < 0.01$) difference in temperature of CB was determined between front and rear legs. Based on the results of this research, the feasibility and usefulness of application of the thermovision camera in early detection of tissue changes on hooves of lactating cows is recognized. Early detection of hoof disease before development of lameness can contribute to production costs reduction and increase of animal welfare.

Key words

infrared thermography, holstein, hoof lesion, coronary band

University of Josip Juraj Strossmayer in Osijek, Vladimira Preloga 1, 31000 Osijek, Croatia
✉ e-mail: mgregic@pfos.hr

Received: May 16, 2017 | Accepted: September 13, 2017

Introduction

Discovery and quantitative definition of infrared radiation by Herschela and Max Planck resulted in development of infrared technologies as well as in routine application of thermovision camera in different fields. Since, every object or entity emits a certain amount of heat visible in the red spectrum of sunlight, the temperature of the body can be used as a good indicator in assessing the health and physiological state of the cow. The temperature of extremity and skin are highly dependent on the circulating flow and the metabolic status of the tissue (Berry et al., 2003). This is easily visible during the inflammatory changes in the organism when, due to enhanced activity of the organism defence and intensification of circulation in the inflammatory part of the body, comes to an increase of the surface temperature. In the visualization and determination of the difference in the surface temperature of the measured body or object, infrared thermography showed as a good method (Alsaad and Büscher, 2012; Novosel, 2016). This method has been widely used in industry, human and veterinary medicine. Furthermore, it was also applied in livestock production (Harper, 2000; Nikkah et al., 2005) and horse breeding (Eddy et al., 2001; Gregić, 2016). The diseases of the hoof and the incidence of lameness in lactating cows is one of the major problems in intensive milk production (Whay et al., 2003). These diseases disrupt the welfare of animals, induce drop of milk production and finally increase the cost of cows breeding, resulting in large economic losses (Green et al., 2002). The aim of the study was to use the thermovision camera to measure the temperatures of the hoof, and early detection of tissue changes before the development of lameness.

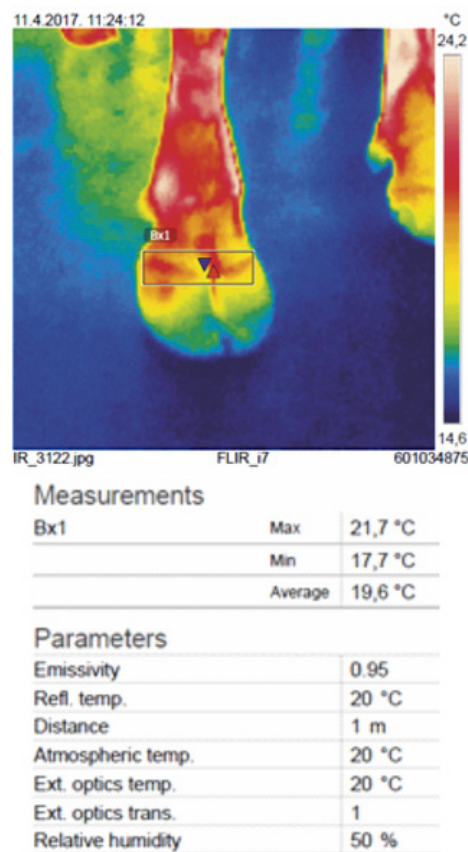
Material and methods

The study was conducted in Holstein cows (n=86), from the first to fourth lactation (with 30-400 days of lactation). Cows were kept at semi-open cattle farms with deep bedding. The cows included in the experiment did not have any visually noticeable changes in the movement (lameness) or on the hooves. In the treatment area, after milking, the measurement of the surface temperature of hooves were conducted by a thermovision camera (Flir and 7, FLIR Systems, Inc., Boston, USA) with 0.95 emissivity. Before measurements the floors and legs of all cows (n=86) were cleansed of impurities. Measurements (shooting) was made from a distance of 1.0 meters from the animal from the front side of the leg. For the analysis of thermal images and determining the temperature of the skin surface hoof FLIR software (7 FLIR and software systems, FLIR Systems Inc., Boston, USA) was used. Measurement of temperature of coronary band (CB) is shown in Figure 1. The ambient temperature during the shooting was between 18.5 - 20.5°C. Based on the analysis of thermovision pictures and detection of the areas of hooves with higher differences in tissue temperatures (area with visible lower and higher temperatures) 30 cows were isolated as suspected to having a tissue changes as follows:

- 1) Sole ulcer (SU)
- 2) Interdigital hyperplasia (IH)
- 3) Dermatitis digitalis/interdigitalis (D).

The cows suspected to have tissue changes were examined by an official employee who was trained for inspection and correction of hooves on the farm. Cows that had some kind of tissue change

on a minimum one hoof were characterized as “sick”, while the other cows were classified in the “health” group. For statistical analysis data from “sick” cows were used. In order to compare the mean values of the surface temperature of the non-lesion and lesion hoofs t-test was performed. Furthermore, in order to determine the effect of the leg positions on a surface temperature of the hoofs the analysis of variance (ANOVA) was done, and significance of the differences was tested with Fisher LSD test ($p < 0.0001$). For statistical analysis Statistica (2012) was used.



Picture 1. Thermal image of the hoof with corresponding measured values

Results

After the examination of all the isolated cows (n=30) suspected of having some tissue change (SU, IH, D), it was determined that 63% (n=19) was “sick” cows or cows that had some kind of tissue change on a minimum one hoof (Figure 1). Also, 37% (n=11) of cows were without any tissue change that is estimates of elevated temperature of the tissue with the thermovision camera gave a negative result.

As presented at Figure 2. three different tissue change of the hooves of dairy cows legs, namely: sole ulcers (14%), interdigital hyperplasia (24%) and dermatitis (62%) were determined.

In terms of position of the foot of sick cows (Figure 3) following was determined: on rear legs 18 hoofs (RL=8; RR=10) with dermatitis, 3 hoofs (RL=1 and RR=2) with the interdigital

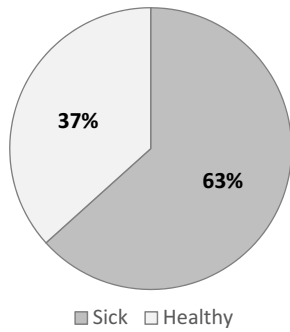


Figure 1. Percentage of healthy and sick cows in the total number of isolated cows suspected to having a tissue change (n=30)

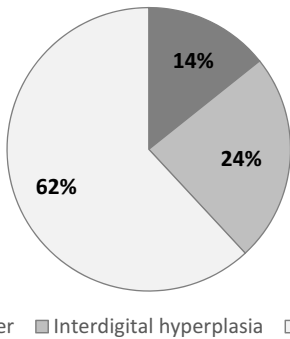


Figure 2. Representation of determined tissue change on cows' hooves (n=19)

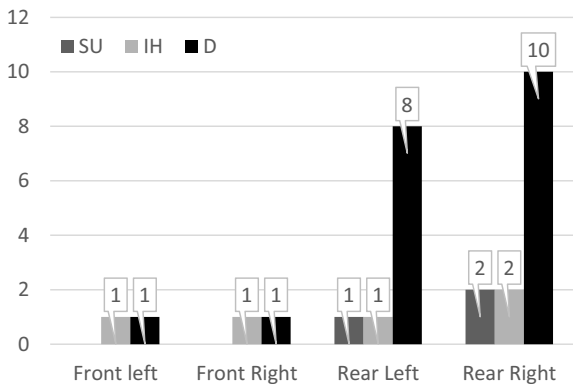


Figure 3. Representation of determined tissue change depending on the position of the legs of cows (n=19); D – Dermatitis digitalis/interdigitalis, IH – interdigital hyperplasia, SU – sole ulcer

hyperplasia, and hooves 3 (RL=1; RR=3) with ulcer. On the front legs, 2 hooves (FL=1; FR=1) with dermatitis and interdigital hyperplasia (FL=1; FR=1) were determined, while ulcer was not confirmed.

In the cows which were classified as “sick” the average temperature of coronary band (CB) on the hooves of the front legs ranged from 12.70 to 24.90°C for left (FL), and from 12.70 to 25.50°C for right (FR) leg. The average CB temperature for FL was 18.00°C and for FR 18.39°C (Table 1). The average CB

Table 1. Descriptive statistics of temperature of coronary band (CB) on the hooves of cows that had some kind of tissue change on a minimum one hoof (Sick cows, n=19)

CB	Mean	Min	Max	SD	SE
FL	18.00	12.70	24.90	4.11	1.06
FR	18.39	12.70	25.50	4.48	1.06
RL	21.97	15.10	27.70	3.29	0.78
RR	21.62	12.90	29.90	4.42	1.01

CB – coronary band, FL – front left, FR – front right, RL – rear left, RR – rear right

Table 2. Mean values of maximum, minimum and mean measured temperature of coronary band (CB) on the hooves of cows in regard to presence of the lesions

CB	Hooves (n ¹ = 19; n ² = 76)		p
	Non-lesion (n ² =51) Mean	Lesion (n ² = 25) Mean	
Max	21.35	27.28	p<0.0001
Min	16.00	18.12	p<0.05
Mean	18.62	22.76	p<0.0001

CB – coronary band; n¹ = number of animals; n² = number of hooves; p = level of significance

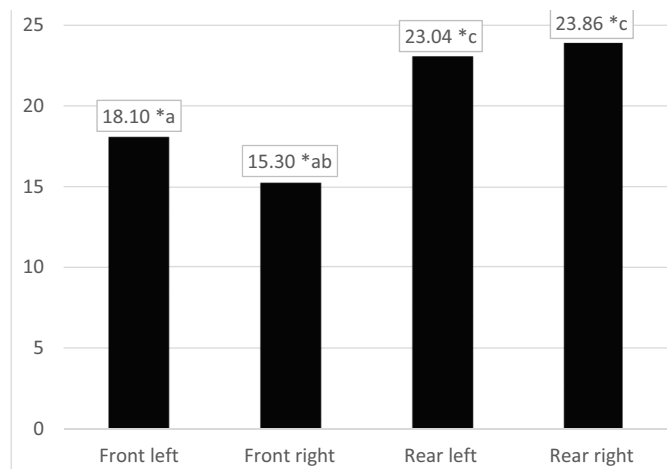


Figure 4. Mean values of measured temperature of coronary band (CB) on the hooves of cows in regard to leg position

temperature for rear left (RL) ranged from 15.10 to 27.70°C, and from 12.90 to 29.90°C for the rear right (RR). The average CB temperature for RL was 21.97°C and 21.62°C for RR (Table 1).

Table 2 represents mean values of minimum, maximum and mean measured of coronary band (CB) on the hooves of cows in regard to presence of the lesions.

At non-lesion hooves following values of temperature of coronary band (CB) on the hooves were determined: average minimum temperature 16.00°C, maximum 21.35°C, and mean

18.62°C. Same parameters for lesion hoof were: 18.12°C, 27.28°C and 22.76°C. Furthermore, statistically highly significant ($p < 0.05$; $p < 0.0001$) difference in maximum, minimum and mean measured temperature of coronary band (CB) on the hooves of cows were determined between the non-lesion and lesion hooves (Table 2).

Mean values of measured temperature of coronary band (CB) on the hooves of cows in regard to leg position are presented on Figure 4. Statistically significant ($p < 0.01$) difference was determined between front left (FL) and both rear legs (RL, RR), as well as between front right (FR) and both rear legs (RL, RR).

Discussion

According to Poikalainen et al. (2012), the body temperature can be used as a good indicator in assessing the health and physiological status of the cow. The same authors determined higher temperature of the body parts with injuries (32.8°C) compared with healthy tissue (27.4–28.2°C). In previous research on cattle that included the use of thermovision cameras, a significant difference in ear skin temperature with the developed inflammatory reaction as a consequence of the use of contaminated implants compared to the skin surface of healthy ears was determined (Spire et al., 1999). Furthermore, significant difference in eye temperature of diseased cattle comparable to healthy ones was determined (Cockroft et al., 2000). Since significant ($p < 0.05$; $p < 0.0001$) difference in the temperature of coronary band on the hooves between lesion and non-lesion hooves was found, the results of this study are in line with previous researches. Analysis of the temperature of coronary band on the hooves of Holstein cows was also conducted by Nikkah et al. (2004). They determined significantly higher temperature of hoofs area in cows in earlier lactation (≤ 200 days in lactation) in comparison to cows in later lactation stage (> 200 days). This is also supported by the results of our previous research with thermovision camera (Bobić et al., 2016) where the significant differences in lactation stage was found between the cows with inflammation on the hooves compared with cows that did not have inflammatory changes (140.32 vs. 235.63 days in milk). The study of hooves diseases on rear legs of cows by Alsaad and Buescher (2012), showed higher temperatures of coronary band compared with the results of this study. The difference could be due to shooting angle. Alsaad and Buescher (2012) measured the back of the hoof, while in this study shooting was done from the front. The same authors have determined the threshold of 0.64°C temperature between CB hoof with and without inflammation, with an 85.7% probability that the test results should be positive (cows with confirmed inflammatory changes or sick cows). The results of this study coincide with the already mentioned, since significantly higher difference in temperature between the CB on lesion and non-lesion hooves of $> 4.0^\circ\text{C}$ was found. The determined percentage of positive cows (sick) was 63%. In earlier research by Bobić et al. (2016) a slightly higher percentage (70%) of hits using a thermovision camera to assess cows with some of the tissue change in the hooves was found. In accordance to Nikkah et al. (2004), the leg position affects the increased occurrence of some hoof disease. Same authors concluded that the incidence of tissue change in the rear legs was higher. Stated was confirmed by the results in this study.

Conclusion

Based on the results of this research, the feasibility and usefulness of application of the thermovision camera in early detection of tissue changes on hooves of lactating cows is recognized. Early detection of hoof disease before development of lameness can contribute to production costs reduction and increase of animal welfare.

References

- Alsaad M., Büscher W. (2012). Detection of hoof lesions using digital infrared thermography in dairy cows. *Journal of Dairy Science*, 95: 735–742.
- Berry R. J., Kennedy A. D., Scott S. L., Kyle B. L., Schaefer A. L. (2003). Daily variation in the udder surface temperature of dairy cows measured by infrared thermography: Potential for mastitis detection. *Canadian Journal of Animal Science*, 83: 687–693.
- Bobić T., Mijić P., Gregić M., Baban M., Gantner V. (2016). Primjena termovizijske kamere u ranom otkrivanju bolesti papaka mliječnih krava. *Krmiva*, 58 (2): 56–59.
- Cockroft P. D., Henson F. M. D., Parker C. (2000). Thermography of a septic metatarsophalangeal joint in a heifer. *The Vet.Rec.*, 26: 258–260.
- Eddy A. L., van Hoogmoed L. M., Snyder J. R. (2001). Review: The role of thermography in the management of equine lameness. *Vet. J.* 162: 172–181.
- Green L. E., Hedges V. J., Schukken Y. H., Blowey R. W., Packington A. J. (2002). The impact of clinical lameness on the milk yield of dairy cows. *Journal of Dairy Science*, 85: 2250–2256.
- Gregić M. (2016). Sposobnost prilagodbe preponskih konja na stres nakon treninga različitih intenziteta. Doktorska disertacija. Sveučilište J. J. Strossmayer u Osijeku, Poljoprivredni fakultet u Osijeku, Osijek, Hrvatska.
- Harper D. L. (2000). The value of infrared thermography in a diagnosis and prognosis of injuries in animals. *Proc., Inframation 2000*, Orlando, USA, 115–122.
- Knížková I., Kunc P., Gürdil G. A. K., Pinar Y., Selvi K. Ç. (2007). Applications Of Infrared Thermography In Animal Production. *O.M.U. Journal of the Faculty of Agriculture*, 22 (3): 329–336.
- Nikkah A., Plaizier J.C., Einarson M.S., Berry R.J., Scott S.L., Kennedy A.D. (2005). Infrared thermography and visual examination of hooves of dairy cows in two stages of lactation. *Journal of Dairy Science*, 88: 2479–2753.
- Novosel N. (2016). Primjena termovizijske infracrvene kamere u termotehnici. Završni rad. Međimursko Veleučilište u Čakovcu, Čakovec, Hrvatska.
- Poikalainen V., Praks J., Veermäe I., Kokkin E. (2012). Infrared temperature patterns of cow's body as an indicator for health control at precision cattle farming. *Agronomy Research Biosystem Engineering Special Issue 1*: 187–194.
- Spire M. F., Drouillard, J. S., Galland J. C., Sargeant J. M. (1999). Use of infrared thermography to detect inflammation caused by contaminated growth promotant ear implants in cattle. *J. Am. Vet. Med. Assoc.* 215:1320–1324.
- Whay H. R., Main D. C., Green L. E., Webster A. J. (2003). Assessment of the welfare of dairy cattle using animal-based measurements: Direct observations and investigation of farm records. *Veterinary Record*, 153: 197–202.

acs82_38